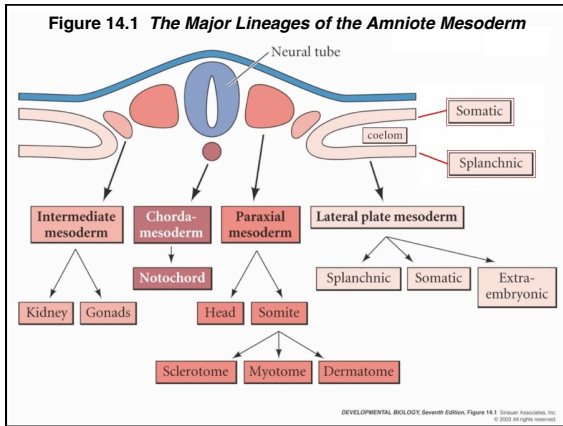


---

---

---

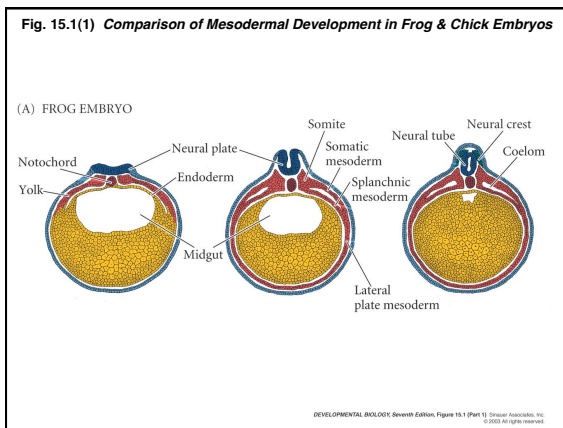
---

---

---

---

---




---

---

---

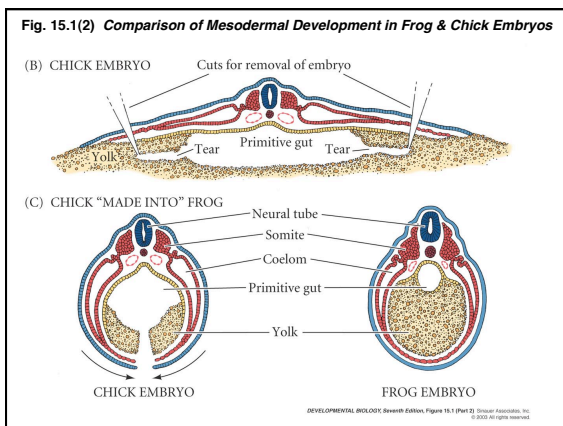
---

---

---

---

---




---

---

---

---

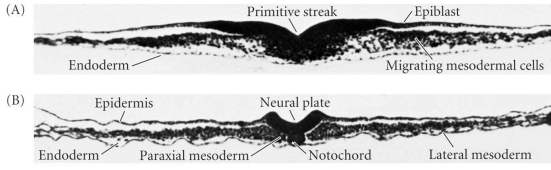
---

---

---

---

**Fig. 14.2(1) Gastrulation & Neurulation in the Chick Embryo: Mesoderm**



DEVELOPMENTAL BIOLOGY, Seventh Edition, Figure 14.2 (Part 1) © 2003 Sinauer Associates, Inc. All rights reserved.

---

---

---

---

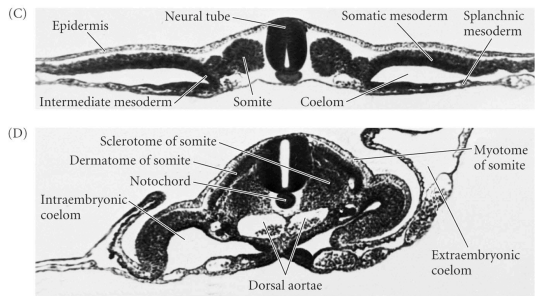
---

---

---

---

**Fig. 14.2(2) Gastrulation & Neurulation in the Chick Embryo: Mesoderm**



DEVELOPMENTAL BIOLOGY, Seventh Edition, Figure 14.2 (Part 2) © 2003 Sinauer Associates, Inc. All rights reserved.

---

---

---

---


---

---

---

---

**Figure 14.4 Neural Tube and Somites**



DEVELOPMENTAL BIOLOGY, Seventh Edition, Figure 14.4 © 2003 Sinauer Associates, Inc. All rights reserved.

---

---

---

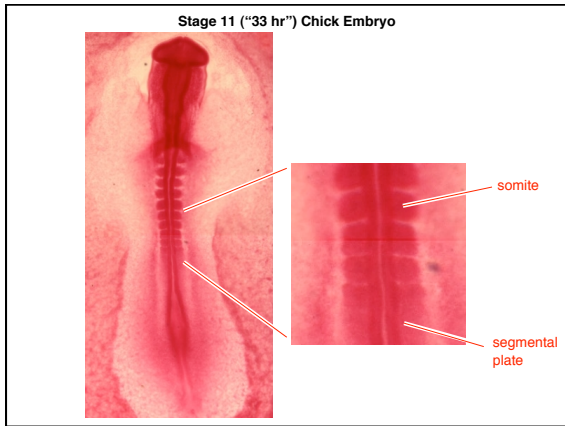
---

---

---

---

---



---

---

---

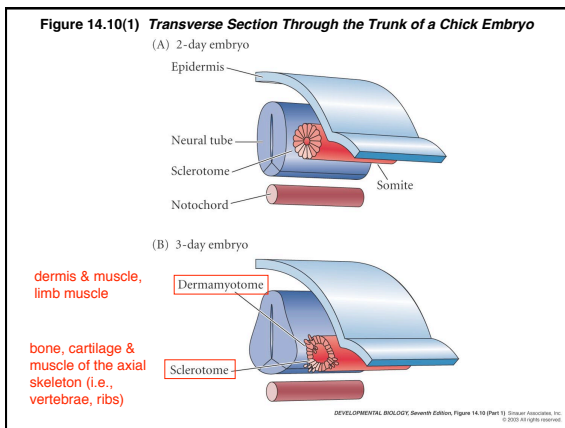
---

---

---

---

---



---

---

---

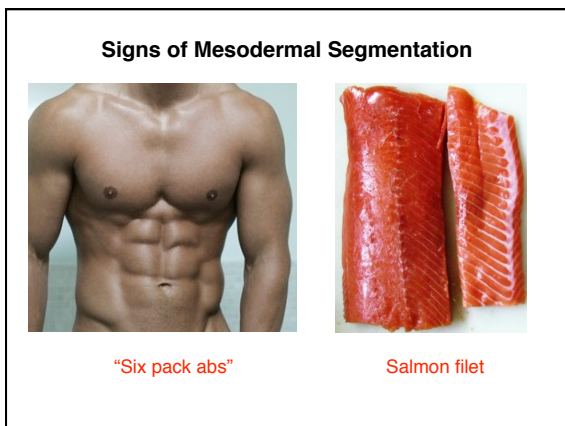
---

---

---

---

---



---

---

---

---

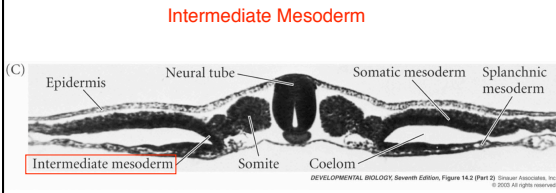
---

---

---

---

**Fig. 14.2C Gastrulation & Neurulation in the Chick Embryo: Mesoderm**



gives rise to kidney, somatic gonad, urogenital ducts

---

---

---

---

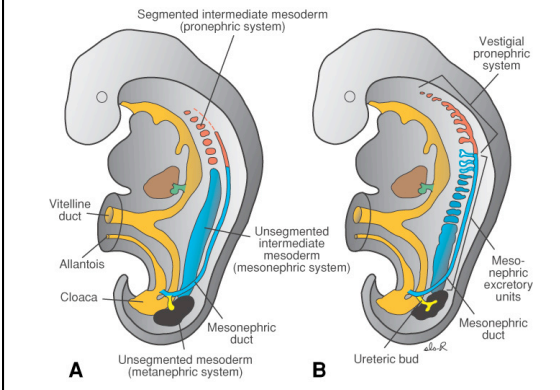
---

---

---

---

**Intermediate Mesoderm in the Human Embryo - Kidney and Urogenital ducts**




---

---

---

---

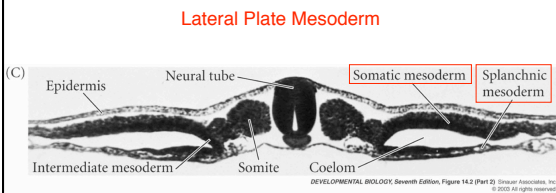
---

---

---

---

**Fig. 14.2C Gastrulation & Neurulation in the Chick Embryo: Mesoderm**



gives rise to heart, major blood vessels, limb mesoderm (except limb muscle), visceral muscle, coelomic linings

---

---

---

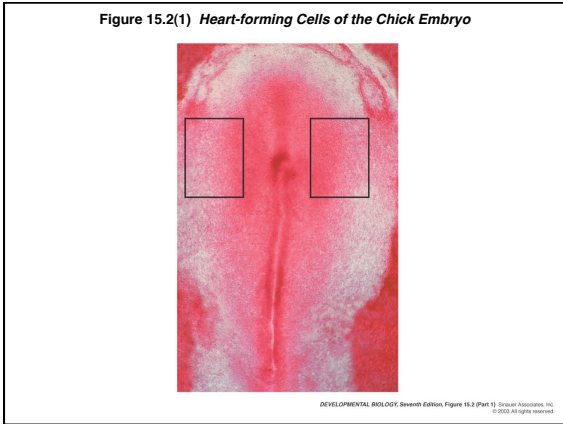
---

---

---

---

---



---

---

---

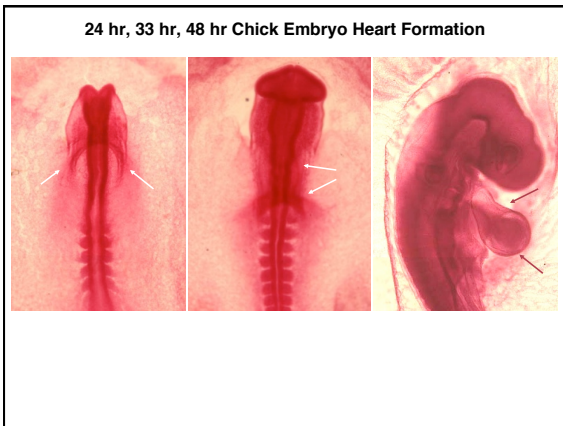---

---

---

---

---



---

---

---

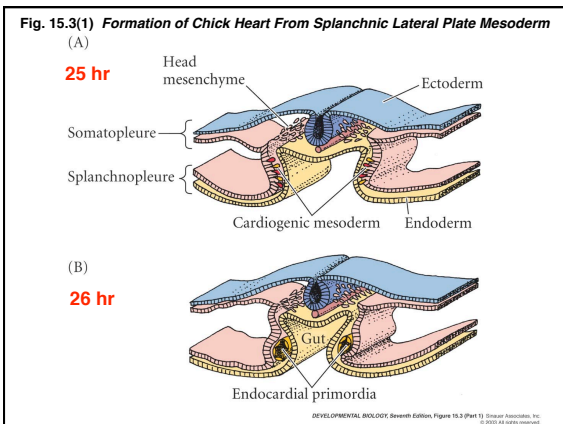
---

---

---

---

---



---

---

---

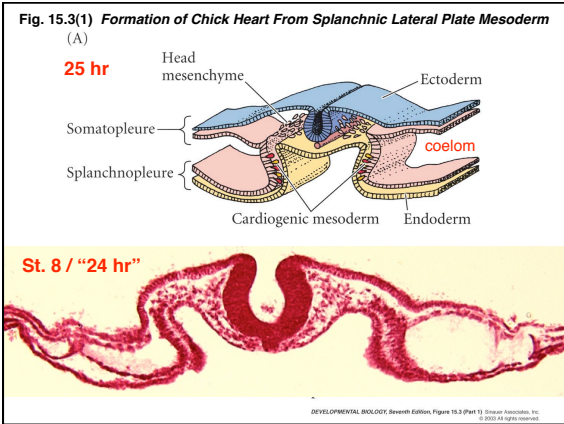
---

---

---

---

---



---

---

---

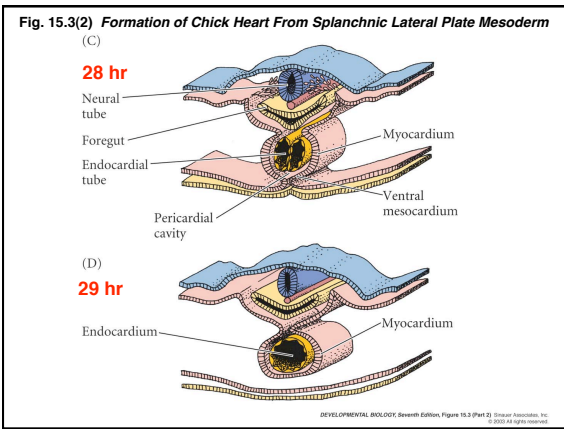
---

---

---

---

---



---

---

---

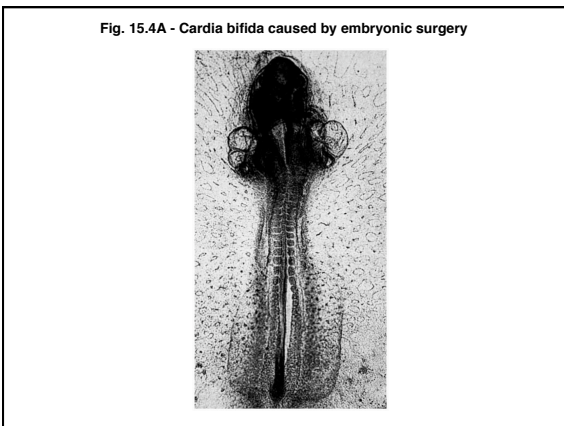
---

---

---

---

---



---

---

---

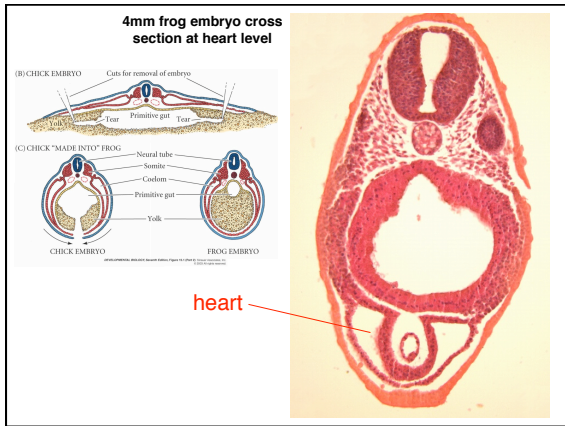
---

---

---

---

---




---

---

---

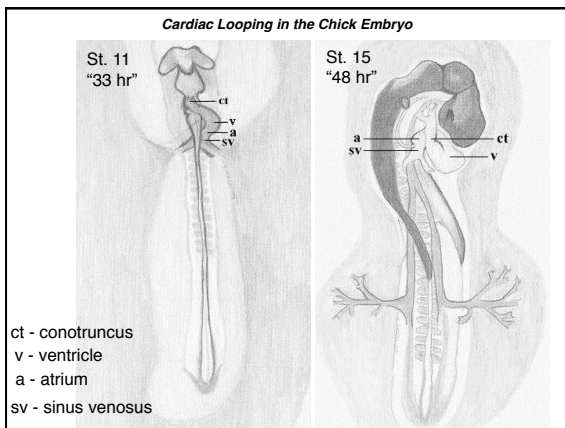
---

---

---

---

---




---

---

---

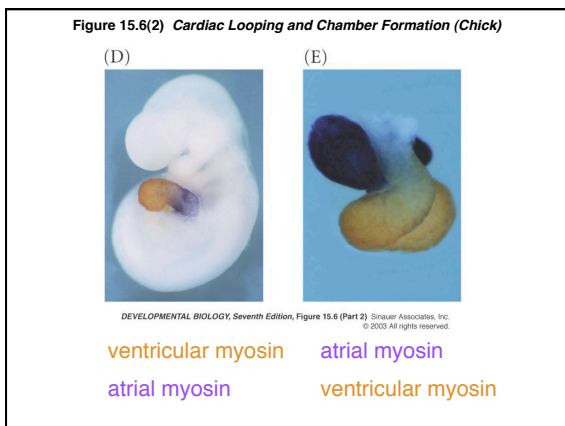
---

---

---

---

---




---

---

---

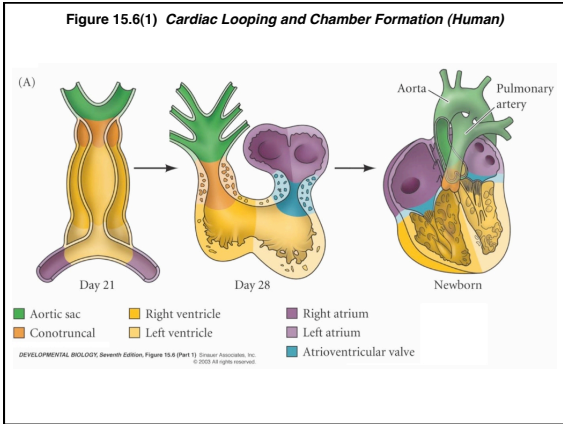
---

---

---

---

---



---

---

---

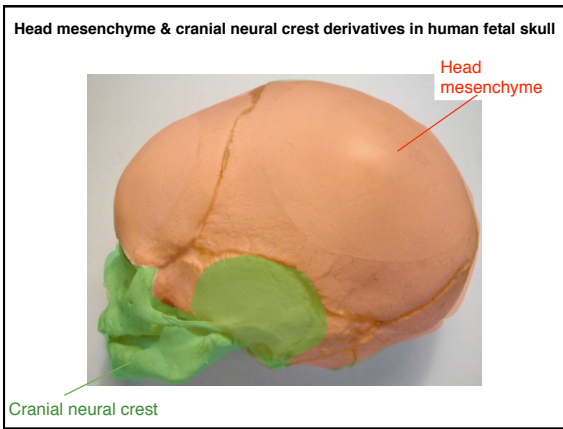
---

---

---

---

---



---

---

---

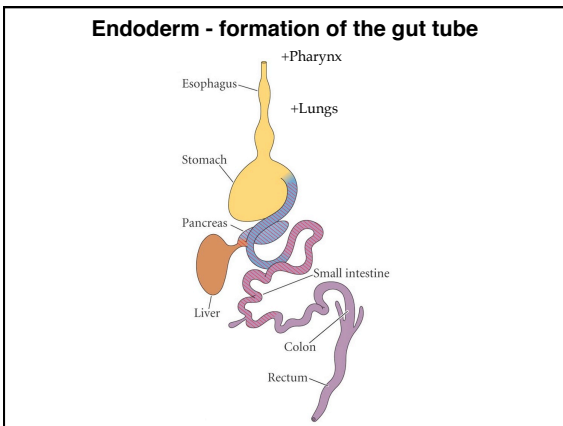
---

---

---

---

---



---

---

---

---

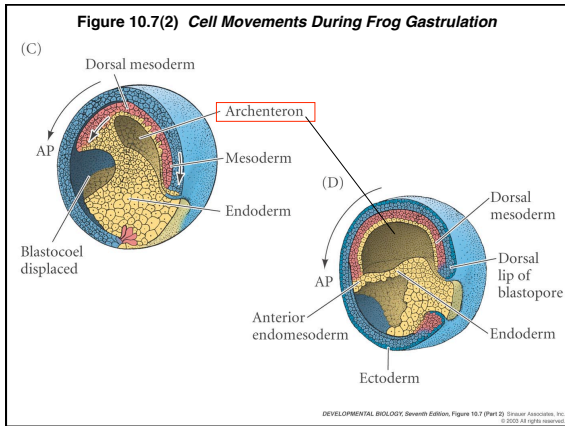
---

---

---

---






---

---

---

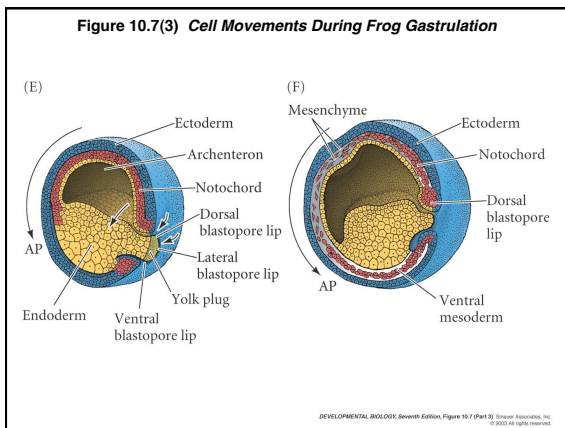
---

---

---

---

---




---

---

---

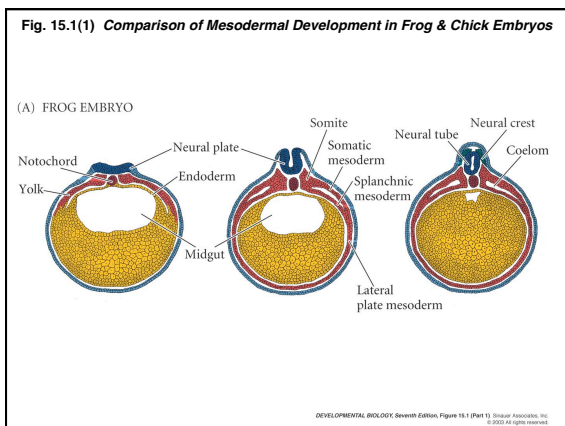
---

---

---

---

---




---

---

---

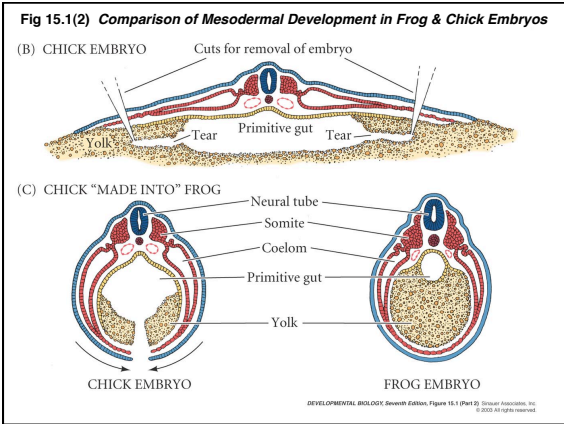
---

---

---

---

---




---

---

---

---

---

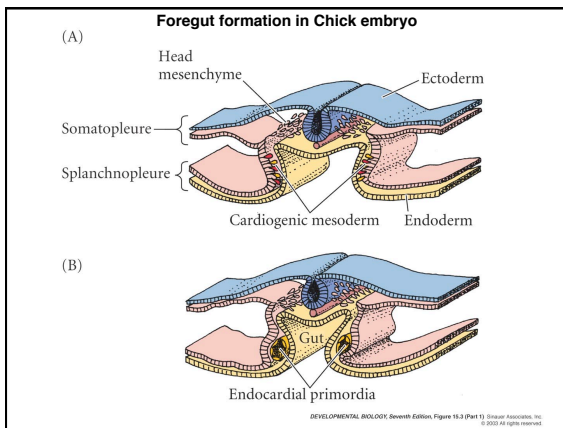
---

---

---

---

---




---

---

---

---

---

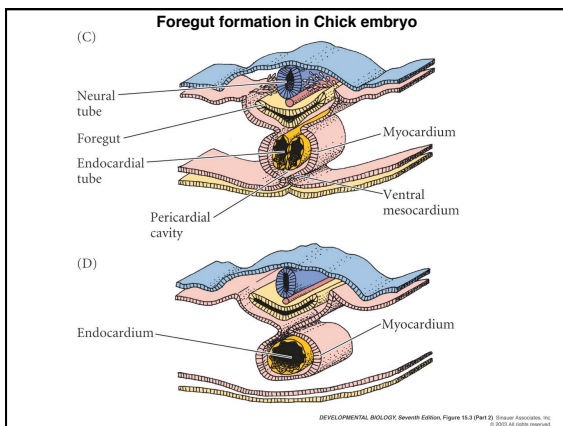
---

---

---

---

---




---

---

---

---

---

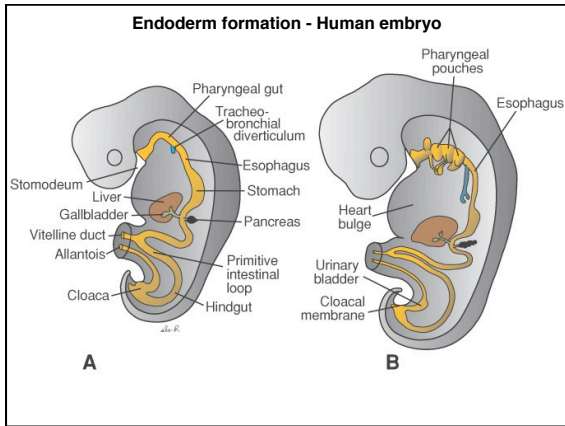
---

---

---

---

---




---

---

---

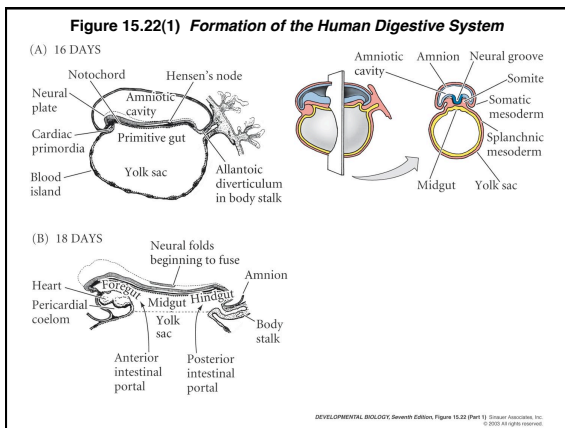
---

---

---

---

---




---

---

---

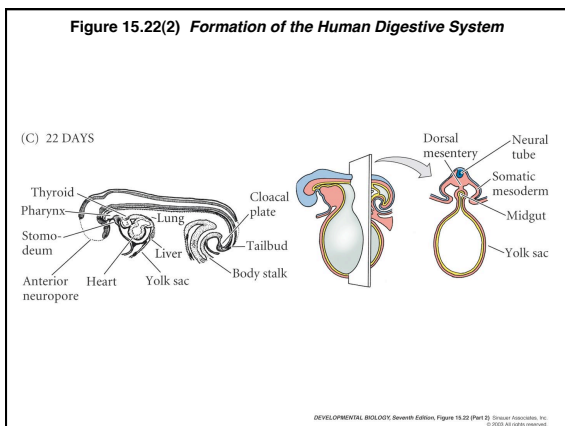
---

---

---

---

---




---

---

---

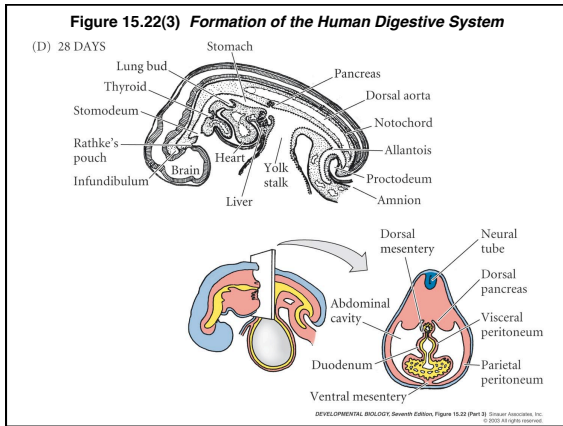
---

---

---

---

---




---

---

---

---

---

---

---

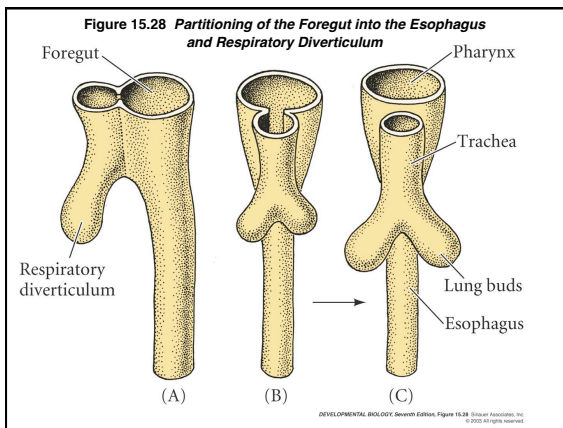
---

---

---

---

---




---

---

---

---

---

---

---

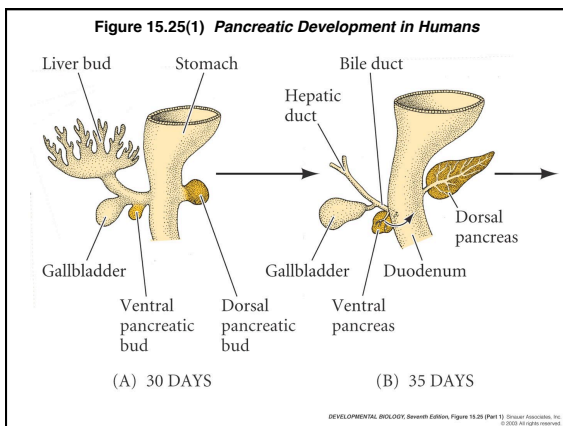
---

---

---

---

---




---

---

---

---

---

---

---

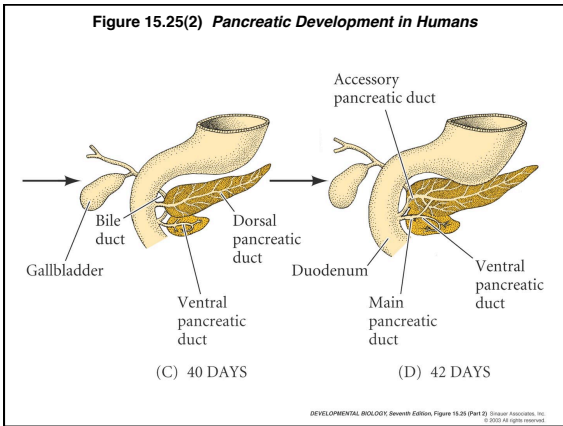
---

---

---

---

---




---

---

---

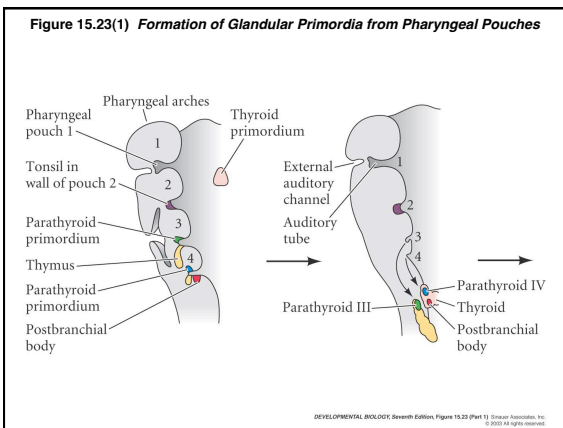
---

---

---

---

---




---

---

---

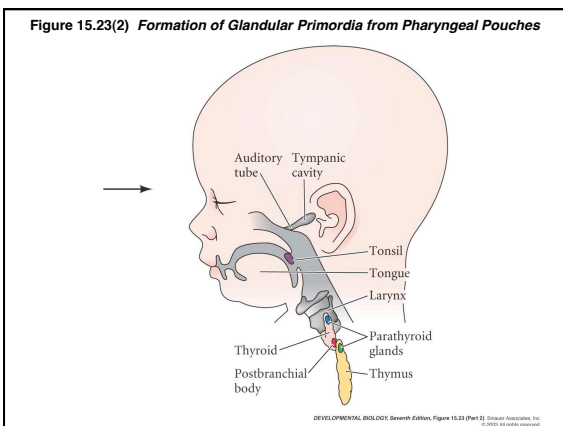
---

---

---

---

---




---

---

---

---

---

---

---

---

**Extraembryonic Membranes**  
- an adaptation of the amniote egg

Somatopleure-derived

Chorion (outermost) - gas exchange / placenta

Amnion - protective, aqueous environment

Splanchnopleure-derived

Allantois - waste collection

Yolk sac (innermost) - surrounds yolk

---

---

---

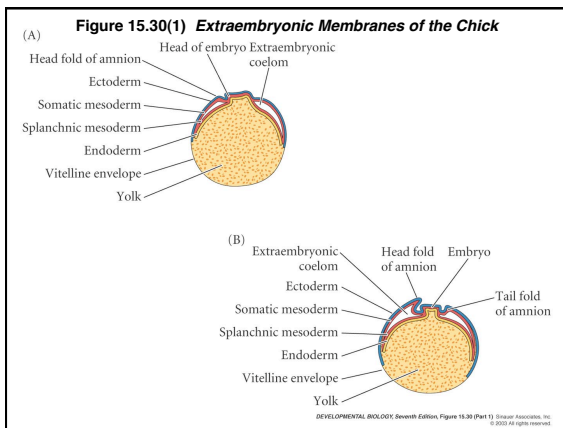
---

---

---

---

---




---

---

---

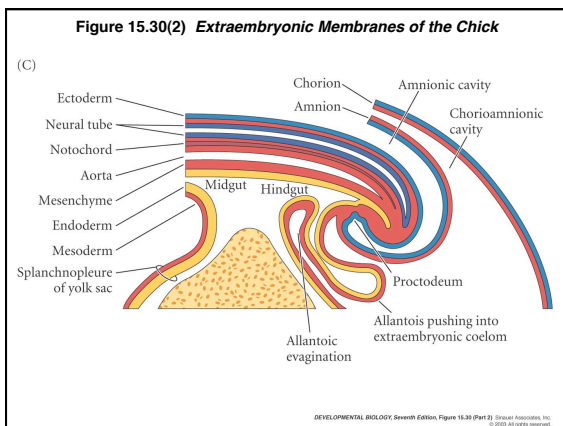
---

---

---

---

---




---

---

---

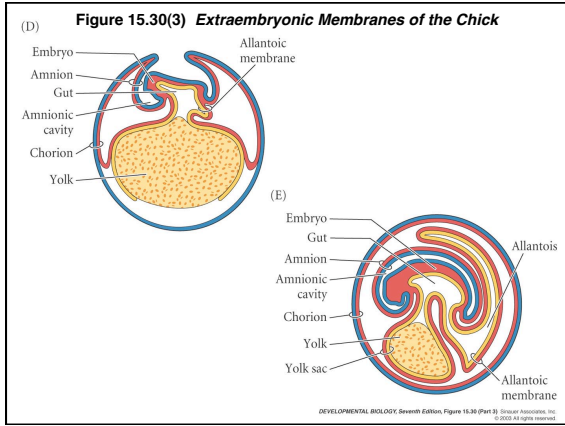
---

---

---

---

---



---

---

---

---

---

---

---

---